



=Abstract=

**Superficial Candidal Infection Occurred on the Site of Epidermal Transplantation**


**Dong Ju Ha and Mu Hyoung Lee**

*Department of Dermatology, College of Medicine, KyungHee University, Seoul, Korea*

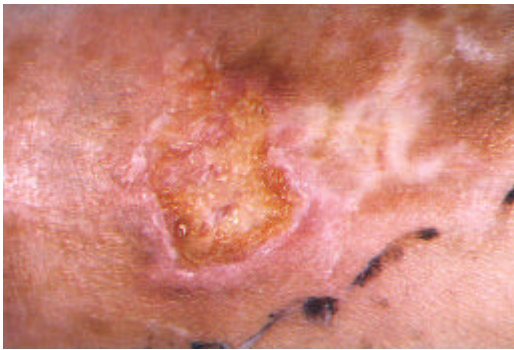An epidermal grafting using the top of suction blister has been used successfully for the treatment of depigmented skin, such as vitiligo, achromic areas after dermabrasion, and burns.

A 9-year-old girl showed the delayed wound healing of epidermal grafting site for the treatment of vitiligo on popliteal fossa. Direct microscopic examination (KOH) from the wound showed numerous hyphae. Fungus culture and germ tube test confirmed *Candida albicans* from the wound surface. The wound healed by antifungal treatment, leaving scar. [**Kor J Med Mycol 5(4): 179-181**]

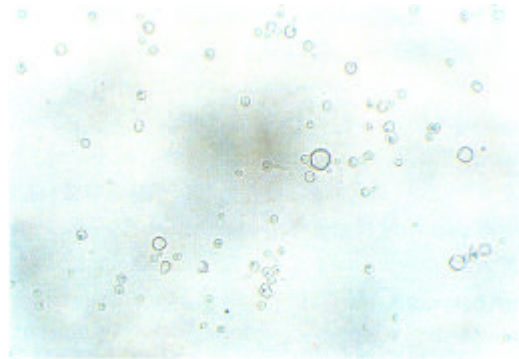
**Key Words:** Epidermal transplantation, Superficial candidal infection



† : , 130-702,  
Tel: (02) 958-8501, Fax: (02) 969-6538  
\* 2000 6 17 7



**Fig. 1.** An unhealed wound with yellowish oozy crust 4 weeks after the procedure of epidermal grafting.



**Fig. 2.** The formation of germ tubes in human serum after 2 hours' incubation at 37°C (x400).

(germ tube test)  
 (Fig. 2) *Candida albicans*  
 2 itraconazole 1  
 150 mg 1% terbinafin

*C. albicans* *C. parapsilosis*  
*C. guilliermondii*가 *C. albicans*  
 4. *C. albicans* 가  
 7. 85~90%가  
 KOH  
*C. albicans*가

*Candida*  
 3. , AIDS 가  
 가  
 4. ,  
 Giandoni 5  
 KOH  
 가  
 가  
 Weiss 6 2 7  
*Candida*가  
 6.5~7.9%  
*Candida*

3. ,  
 8. 가  
 5. 가 가  
 Maibach Kligman<sup>9</sup> (epicutaneous inoculation)  
 36~72  
 1  
 가 ,  
 (再上皮化)가 가  
 4. 가 14

- 1999; 4: 98-103
1. Falabella R. Epidermal grafting. An original technique and its application in achromic and granulating areas. Arch Dermatol 1971; 104: 592-600
  2. Hann SK, Im S, Bong HW, Park YK. Treatment of stable vitiligo with autologous epidermal grafting and PUVA. J Am Acad Dermatol 1995; 32: 943-948
  3. Martin AG, Kobayashi GS. Yeast infections: candidiasis, pityriasis versicolor. In: Freedberg IM, Eisen AZ, Wolff K, et al., eds. Dermatology in general medicine, 5th ed. New York: McGraw-Hill, 1999: 2358-2371
  4. , , .
  5. Giandoni MB, Grabski WJ. Cutaneous candidiasis as a cause of delayed surgical wound healing. J Am Acad Dermatol 1994; 30: 981-984
  6. Weiss CA 3rd, Statz CL, Dahms RA, Remucal MJ, Dunn DL, Beilman GJ. Six years of surgical wound infection surveillance at a tertiary care center: review of the microbiologic and epidemiological aspects of 20,007 wounds. Arch Surg 1999; 134: 1041-1048
  7. Ray TL, Wuepper KD. Recent advances in cutaneous candidiasis. Int J Dermatol 1978; 17: 683-690
  8. Rosman N. Oropharyngeal and cutaneous candidosis in patients with decreased resistance to infections. Acta Derm Venereol Suppl (Stockh) 1986; 121: 47-49
  9. Maibach HI, Kligman AM. The biology of experimental human cutaneous moniliasis (*Candida albicans*). Arch dermatol 1962; 85: 233-254
-