

가 , \*  
\* . . . .

=Abstract=

**Clinical and Mycological Studies of Dermatophytosis in Human Transmitted from Infected Rabbits**

Sook Hee Lim, Dong Houh\*, Hyun Jeong Park, Seung Cheol Baek and Dae Gyoo Byun

Department of Dermatology, College of Medicine, The Catholic University of Korea, and Department of Dermatology, Kangdong Sacred Heart Hospital, College of Medicine Hanlym University\*, Seoul, Korea

**Background:** Recently, as rabbits have become a popular pet in Korea, there has been an increase in reports of dermatophytosis in humans as a result of frequent contact with rabbits.

**Objective:** The purpose is to investigate the clinical and mycological features of dermatophytosis in humans transmitted from rabbits.

**Methods:** Seventeen cases of dermatophytosis, developed after contact with rabbits, were clinically evaluated from November, 1999 to May, 2000. Mycologic studies were carried out from the lesions of rabbits and humans.

**Results:** Dermatophytes were cultured from 15 of 17 (88.2%) specimens from the lesions of humans. *Trichophyton (T.) mentagrophytes*, granulosum-asteroid form, was isolated in 12 specimens (70.6%) and *Microsporum (M.) canis* was isolated in 3 specimens (17.6%). Human infection showed a high incidence in young children under age 10 (52.9%), with female predominance (2 times), and high familial incidence, and mainly being tinea faciale and tinea corporis. Tinea capitis also was observed in four cases, and *M. canis* was isolated from two of them.

**Conclusion:** Rabbits can be an infectious source of human ring-worm due to *T. mentagrophytes* and *M. canis*. These zoophilic dermatophytes can be frequently transmitted to humans and induce inflammatory lesions. Therefore, epidemiologic studies of the prevalence of dermatophytes in healthy or infected rabbits, and sanitary measure are necessary. [Kor J Med Mycol 5(4): 160-166]

**Key Words:** Rabbits, Dermatophytes, Human infection

(zoophilic) (anthropophilic)

(geophilic), ,

† : , 422-717 2 , 가 가  
Tel: (032) 340-2115~7, Fax: (032) 340- 2118, E-mail: hofaderm@unitel.co.kr

가 :  
 1. 가  
 가 가 , 1999 (己卯年)  
 가 가 1999 11 2000 5  
 가 가 17  
 가 가 2,3 , 1 16  
 Trichophyton (T.) mentagrophytes 가  
 T. verrucosum, Microsporum (M.) nanum, M. canis 4 . 20% KOH Sabouraud dextrose  
 가 2-5 , T. mentagrophytes  
 T. mentagrophytes potato dextrose agar 2-3  
 17 T. mentagrophytes lactophenol cotton-blue  
 phytes M. canis 가 , urease

**Table 1.** Clinical features of 17 cases of dermatophytosis transmitted by rabbits

Age (yr) /sex	Site	Contact with Rabbit	Skin disease in rabbit	Family member	Isolates
11/F	Left forearm	(+)	(+)	(-)	(-)
20/F	Face, forearms	(+)	(+)	(+)	<i>M. canis</i>
3/F	Face	(+)	(-)	(-)	<i>T. mentagrophytes</i>
7/F <sup>1</sup>	Face	(+)	(+)	(+)	<i>T. mentagrophytes</i>
5/M <sup>1</sup>	Face, left wrist	(+)	(+)	(+)	<i>T. mentagrophytes</i>
34/F <sup>1</sup>	Buttock	(+)	(+)	(+)	<i>T. mentagrophytes</i>
10/F	Face, neck, scalp	(+)	(+)	(+)	<i>T. mentagrophytes</i>
8/M	Face, scalp	(+)	(+)	(+)	<i>T. mentagrophytes</i>
13/F <sup>2</sup>	Face, trunk, extremities	(+)	(+)	(+)	<i>T. mentagrophytes</i>
45/F <sup>2</sup>	Left shoulder	(+)	(+)	(+)	<i>T. mentagrophytes</i>
12/M	Right arm, legs	(+)	(-)	(-)	(-)
7/F	Scalp	(+)	(+)	(-)	<i>M. canis</i>
4/M	Face	(+)	(+)	(-)	<i>T. mentagrophytes</i>
7/F	Face, trunk, arms	(+)	(+)	(-)	<i>T. mentagrophytes</i>
8/M	Face, scalp	(+)	(-)	(-)	<i>M. canis</i>
9/F*	Face, neck	(+)	(+)	(+)	<i>T. mentagrophytes</i>
10/M	Face	(+)	(+)	(-)	<i>T. mentagrophytes</i>

<sup>1,2</sup>: Members in a family who have had same symptoms

\*: A patient who only touched rabbit, not raised rabbit at home

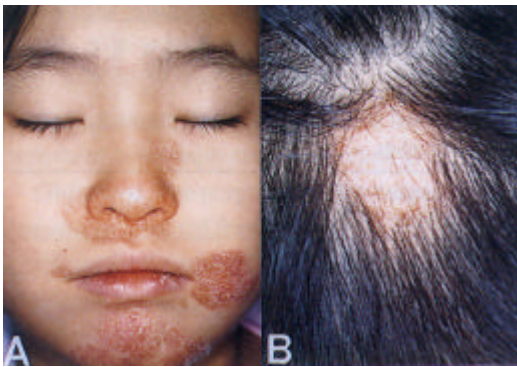. *M. canis*  
lactophenol cotton-blue

. 1

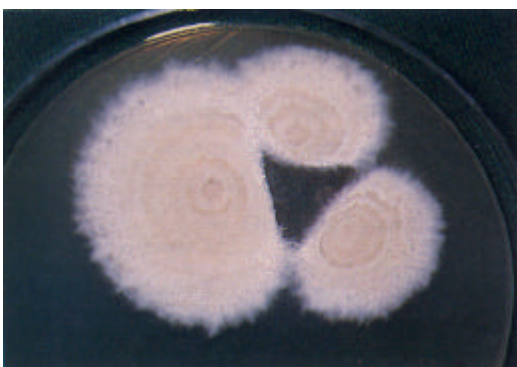KOH

**Table 2.** Distribution of age and sex in patients

Age (Yr)	Sex		Total
	Male	Female	
< 10	4	5	9
10-19	2	3	5
19 <	0	3	3
Total	6	11	17



**Fig. 1.** Multiple, round, inflamed scaly patches on the face (A) and an erythematous scaly alopecic lesion on the scalp (B).



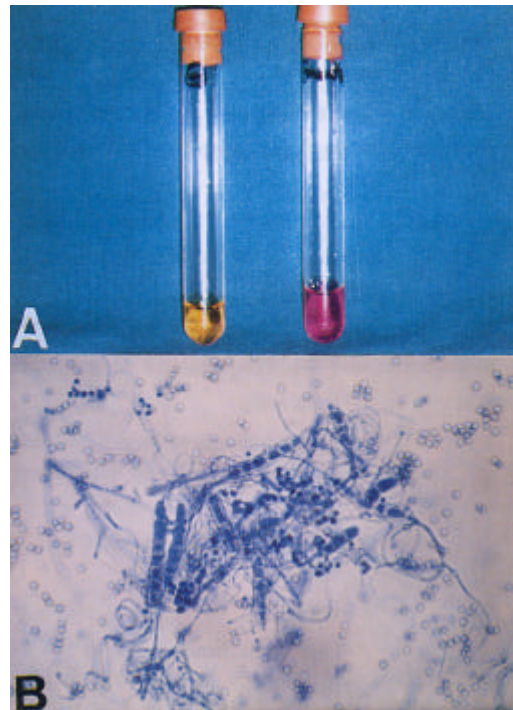
**Fig. 2.** Fine yellow-brown granular colonies of granulose-asteroides form of *T. mentagrophytes* isolated from the lesions of human on the potato dextrose agar after 10 days of incubation at room temperature.

1.

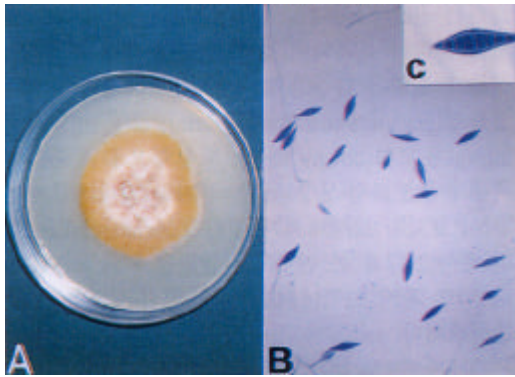
Table 1

3	41 (	12.5 )	10
가 9	(52.9%)	가	가
6 ,	가 11	2	(Table 2).
2		가	
	, 가		
가		가	가
6가 9	,		가 8

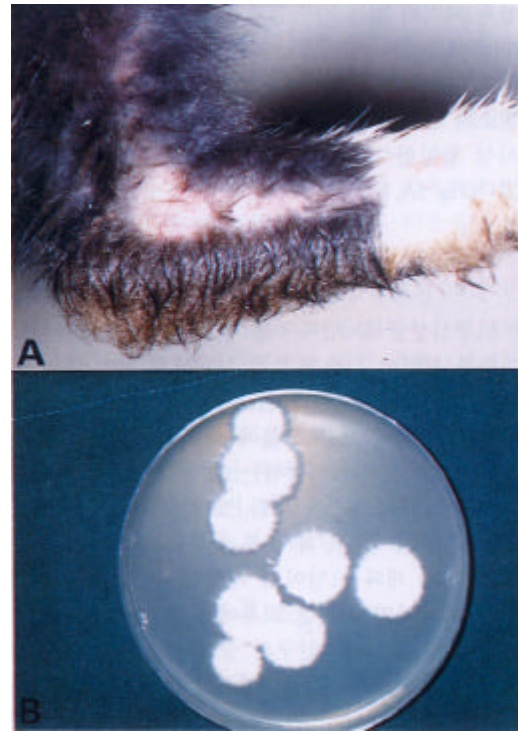
13가 16 , 1



**Fig. 3.** Isolates cultured in the urea showed pink color (A), microscopically, many pencil-shaped macroconidia, grape-like arranged abundant spherical microconidia, and spiral hyphae, characteristics of *T. mentagrophytes*, can be observed (B: Lactophenol cotton blue stain,  $\times 400$ ).



**Fig. 4.** A yellow-whitish colony with marginal saw-tooth appearance on the potato dextrose agar after 14 days of incubation at room temperature (A), microscopically, many fusiform 6-septated macroconidia can be observed (B: Lactophenol cotton blue stain,  $\times 200$ , C:  $\times 1000$ ).



**Fig. 5.** An erythematous scaly alopecic patch on the leg of rabbit (A) and fine yellow-brown granular colonies of granulosum-asteroides form of *T. mentagrophytes* isolated from the lesion of infected rabbit on the potato dextrose agar after 10 days of incubation at room temperature (B).

10 17 2  
 13가 가 3  
 가  
 1~2  
 가  
 가 11 11가 14  
 , 1 가  
 가 4  
 , , 가 ,  
 4 가 3~4  
 1 30  
 가

(Fig. 1 A, B).

3~4 itraconazole

2.

KOH

가

가

6

15 (88.2%)  
*T. mentagrophytes* 가 12 (70.6%),  
*M. canis* 가 3 (17.6%)

*T. mentagrophytes*

가

(Fig. 2).

urease

(Fig. 3A),

가

(Fig. 3B).

*M. canis*

가

*T. mentagrophytes*

(Fig. 4A, B).

*T. rubrum*

1

(Fig. 5A, B). *T. mentagrophytes*가 (granulosum-asteroides form), (powdery form), (downy form), 가 1.

2 *T. mentagrophytes*

21 *T. mentagrophytes*

12

가 *T. mentagrophytes*가 가

, *M. canis*

가 4-8. 8 30.2%

*M. canis*가 , Torres-Rodriguez 4

220 2 *M. canis*

Ali-Shtayeh 6

Cabanes 8 *M. canis*

1. *M. canis*

, 1999

가 가 가 2,3.

가 *M. canis*

가 *M. canis* 가

가 *M. canis* 가 , 가 9

4-7. Torres-Rodriez 4 1,10,11

3.2%가 *T. mentagrophytes*

, Ali-Shtayeh 6 *M. canis*가

61.4%가 7

53 *M. canis*가 가

86.4% *T. mentagrophytes* *M. canis*

가 ,9 (17%)

*T. mentagrophytes*가

69.2% 79.5% 가 4 2 *M. canis*가

*T. verrucosum*, *M. nanum*, *M. canis*

4-7. *T. mentagrophytes*

가 *T. mentagrophytes*가

2,3, *T. mentagrophytes* 가

*T. mentagrophytes*가 *T. mentagrophytes*

3 *M. canis*가

*T. mentagrophytes* *M. canis*가

:  
 .  
 , , 가 ,  
*T. mentagrophytes* *M. canis*  
 2 9~42 10  
 90.4% , 10  
 가 52.9% 가 .  
 가  
 4 ,  
 가 가 , 가  
 2 가 가  
 가 ,  
 가  
 가 .  
 1999 11 2000 5 7  
 17  
 1. 147가 17 , 3~13  
 가 가  
 가 2 ,  
 , 가  
 가 가 6가 9 .  
 2. (12 ) , , 가 ,  
 , (4 ) .  
 , 30

- 가
3. 13가 16 1
  4. 15  
12 *T. mentagrophytes* - , 3  
*M. canis*가 가  
*M. canis* 가  
, 가 *T. menta-*  
*grophytes* - .
  1. . 1997; 2:  
1-8
  2. , . *Trichophyton*  
*mentagrophytes*  
1999; 4: 117-123
  3. , , 가 . 1999; 4  
1: 31
  4. Torres-Rodriguez JM, Drona MA, Rossell J, Ma  
drenys N. Incidence of dermatophytoses in rabbit  
farms in Catalonia, Spain, and its repercussion on  
human health. *Eur J Epidemiol* 1992; 8: 326-329
  5. , . Ring-  
worm  
1997; 21: 391-394
  6. Ali-Shtayeh MS, Arda HM, Hassouna M, Shaheen  
SF. Keratinophilic fungi on the hair of cows, don-  
keys, rabbits, cats, and dogs from the West Bank of  
Jordan. *Mycopathologica* 1988; 104: 109-121
  7. , , , . 7  
, 2000; 28
  8. Cabanes FJ, Abarca ML, Bragulat MR. Derma-  
tophytes isolated from domestic animals in Barce-  
lona, Spain. *Mycopathologica* 1997; 137: 107-113
  9. , . *M. canis*

- . 38  
, 1986; 15
10. , . *Microsporun canis*  
1983; 21: 695-701
11. , . *Microsporun canis*
- . 1977; 15: 1-13
12. Simaljakova M, Buchvald J, Olexova B. *Microsporun canis* infection in rabbits and its transmission to humans. *Mycoses* 1989; 32: 93-96
-