

Isolation of *Trichophyton rubrum* from Diabetic Foot Ulcers of 4 Patients

Weon Ju Lee[†], Kyung Hea Park, Yong Hyun Jang, Seok-Jong Lee and Do Won Kim

Department of Dermatology, Kyungpook National University School of Medicine,
Daegu, Korea

= Abstract =

Trichophyton rubrum is a common cause of superficial dermatophytosis in humans, such as tinea pedis, tinea unguium, tinea corporis and tinea cruris. *T. rubrum* usually attaches to keratin of the epidermis and uses it as a source of nutrients. Therefore, isolation of *T. rubrum* from non-keratinous skin, such as ulcer, is very rare. We describe 4 patients with *T. rubrum*-infected diabetic foot ulcer.

[Korean J Med Mycol 2014; 19(1): 9-12]

Key Words: Diabetic foot ulcers, *Trichophyton rubrum*

INTRODUCTION

Trichophyton rubrum is an anthropophilic fungus causing a chronic superficial dermatophytosis with remissions and relapses. It is the most common dermatophyte worldwide. In addition, it is the dermatophyte most frequently isolated from humans¹. It is not endogenous pathogen. Its transmission occurs most often from person to person, such as within families^{2,3}. Infection with *T. rubrum* is more common in adults and in males than in children and in women. The organism may remain viable in the environment, such as clothing, furniture and hair, for over six months, thus accounting for widespread infections^{2,4}. Arthroconidia and mycelia fragments of *T. rubrum* are the infectious agents. The organism has ability to

form molecular attachments to keratin and use it as a source of nutrients, colonizing keratinized tissues, including the stratum corneum of the skin, developing tinea pedis, tinea corporis, tinea barbae, tinea manuum, tinea cruris and tinea capitis⁵⁻⁷. Uncommon infection like granulomatous disease or extensive and severe disease is also seen⁸⁻¹¹. However, it is rare to isolate *T. rubrum* from oozing nonkeratinized skin wounds.

CASE

Fungal culture was performed in the cutaneous ulcerative lesions of 4 hospitalized patients as a routine laboratory examination. Superficial swabs were taken from the oozing ulcerative wounds for fungal culture. KOH examination and biopsy were not performed in the wounds. They had probable

Received: December 27, 2013, Revised: December 27, 2013, Accepted: January 2, 2014

[†]Corresponding author: Weon Ju Lee, Department of Dermatology, Kyungpook National University School of Medicine, 130, Dongduk-ro, Jung-gu, Daegu 700-721, Republic of Korea.

Tel: +82-10-7730-8877, Fax: +82-53-426-0770, e-mail: weonju@knu.ac.kr

Copyright©2014 by The Korean Society for Medical Mycology (pISSN:1226-4709). All right reserved.

©This is an open-access article distributed under the terms of the Creative Commons Attribution Non-Commercial License(<http://creativecommons.org/licenses/by-nc/3.0/>), which permits unrestricted non-commercial use, distribution, and reproduction in any medium, provided the original work is properly cited. <http://www.ksmm.org>

Table 1. Demographics, isolation date and underlying disease of patients with *T. rubrum*-positive wound culture

No.	Sex	Age	Isolation date of fungus/ bacteria (Days)	Underlying disease	Isolation of fungus/bacteria	Wound site
1	M	76	38 /38	DM, ESRD, ischemic heart disease	<i>T. rubrum</i> / <i>Staphylococcus aureus</i>	Foot
2	M	61	23/-7	DM, AF, heart failure, CRF	<i>T. rubrum</i> / <i>Staphylococcus epidermidis</i>	Foot
3	M	70	43/43	DM, arrhythmia	<i>T. rubrum</i> / <i>Staphylococcus</i> . coagulase negative	Foot
4	M	62	71/47	DM, ESRD due to nephropathy	<i>T. rubrum</i> / <i>Pseudomonas aeruginosa</i>	Foot

No.: number, Isolation date: duration between admission and isolation, DM: diabetes mellitus, ESRD: end stage renal disease, AF: atrial fibrillation, CRF: chronic renal failure

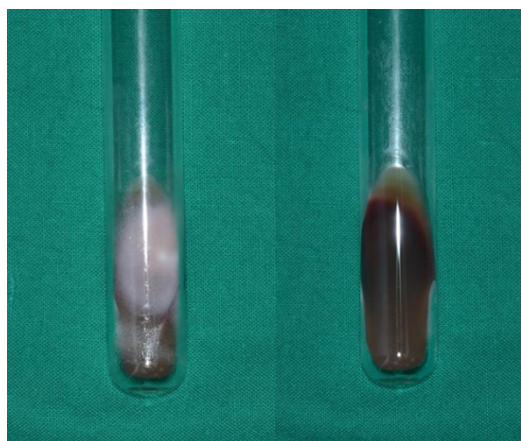


Fig. 1. *Trichophyton rubrum* from case 1 showing white and fluffy colonies on Sabouraud dextrose agar with reddish reverse side.

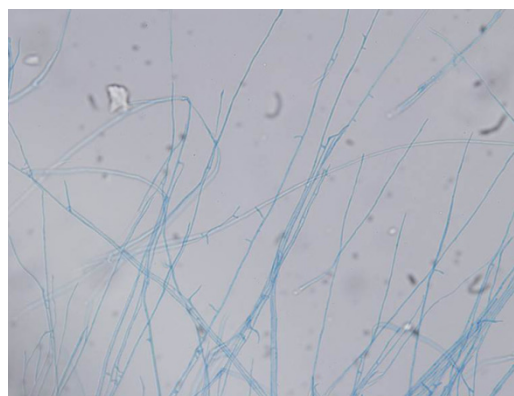

Fig. 2. Microscopic figure of *Trichophyton rubrum* from case 1 showed teardrop-shaped microconidia and long hyphae stained with lactophenol cotton blue ($\times 400$).

tinea pedis and tinea unguium. *T. rubrum* was isolated from the wound exudate of the patients. Colonies of *T. rubrum* cultured on the Sabouraud dextrose agar were white and fluffy showing red color on the reverse side (Fig. 1). Microscopic examination of *T. rubrum* cultured on the Sabouraud dextrose agar revealed teardrop-shaped microconidia and long hyphae (Fig. 2).

All of the patients with *T. rubrum*-infected skin ulcer were male (Table 1). The skin ulcers were diabetic foot ulcer developed due to diabetes

mellitus (Fig. 3A-B). They also had other underlying diseases such as end stage renal disease, ischemic heart disease, heart failure and chronic renal failure (Table 1). They were ranged from 61 to 76 years old (an average age of 67.3 years) (Table 1). Blood culture for fungus was negative. *T. rubrum* was isolated from the skin ulcer at the postadmission date from 23 to 71 days (an average of 43.8 days) (Table 1). In addition, precedent or concomitant bacterial infections were isolated from the wounds (Table 1). All patients had received antibiotics for skin ulcer but not antifungals. The

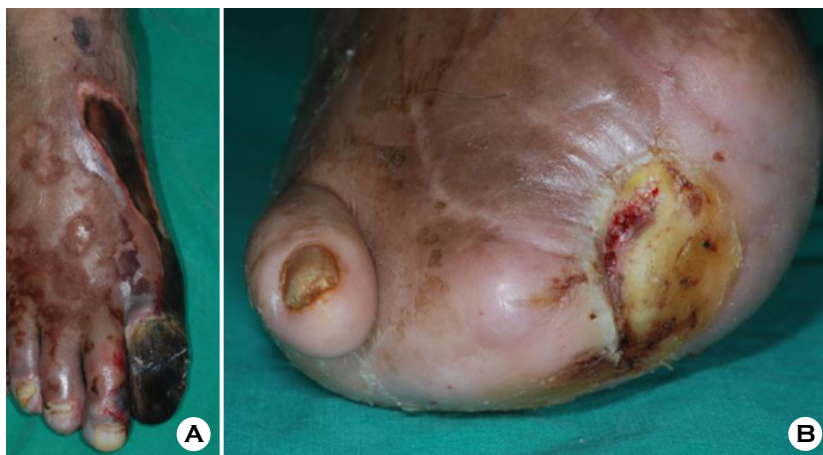


Fig. 3. Clinical pictures of patients are presented. (A) oozing necrotic wounds of case 1. (B) oozing ulcerative wound of case 4.

ulcerative lesions were resistant to treatment for wound healing.

DISCUSSION

Many studies have been done on the prevalence and spectrum of bacterial infections, the role of systemic/local antibiotics, and their effect on wound healing. However, the magnitude of fungal infections in skin wounds has received very little attention. Therefore, clinicians and surgeons do not perform routine fungal culture from wound bed, due to either lack of literature support or assumption of little possibility of fungal infections in the wounds. However, recent studies showed high prevalence of fungal infection in wounds. Chellan et al.¹² had reported 27.9% positive fungal cultures in 318 diabetic patients with wounds. Banasl et al. had reported 9% isolation of fungi from superficial swabs taken from 103 patients with diabetic foot wounds¹³. And, previous studies had shown relatively wide spectrum of fungi (over 18 different species) which were cultured from deep tissue of wounds. *Candida* has been the most predominantly isolated fungus, whereas *T. rubrum* has been very

rarely reported. A few cases, including patient with *T. rubrum*-infected ulcerative lesion, have been reported in Korean mycological literature¹⁴.

These cases bring us into new insights that *T. rubrum* can be cultured from oozing skin wounds. Mycotic infections of wounds may be caused by primary fungal pathogens, opportunistic fungi, hematogenous spreading, break of tissue integrity and wound contamination. Risk factors for mycotic wound infections include extremes of age, long lasting and broad spectrum antimicrobial therapy, diabetes mellitus, immunosuppression, malignancy, X-ray therapy and surgery. The patients included in this report had underlying diseases, as showing the possibility to develop mycotic wound infection due to *T. rubrum*. In addition, all the patients had probable fungal infections, such as tinea pedis and tinea unguium. Usually, diabetes mellitus may increase the risk of mycotic infection in feet. Mayser et al.¹⁵ showed that significant correlation was found between fungal infection and the gender and the age of the diabetic patients. Eckhard et al.¹⁶ reported that the prevalence of fungal infection was significantly higher for diabetic patients with less controlled blood glucose. However, studies

on fungal infections in skin wounds have been conducted in a limited number of patients. We report extraordinary isolation of *T. rubrum* from oozing skin wounds. We think careful examination on fungal infections of skin wounds should be required with routine culture and long-term observation to get much more information, including effect on wound healing and efficacy of antifungal agents. This report showed that it might be possible for fungal infection to delay wound healing. It is important to study the pathogenicity of fungi in oozing skin wounds and their possible contribution to delayed wound healing. In addition, the role of antifungal agents in wound management needs to be evaluated further.

REFERENCES

1. Ajello L. Geographic distribution and prevalence of the dermatophytes. *Ann N Y Acad Sci* 1960;89:30-38
2. Georg LK. Epidemiology of the dermatophytoses--sources of infection, modes of transmission and epidemiology. *Ann N Y Acad Sci* 1960;89:69-77
3. Many H, Derbes VJ, Friedman L. *Trichophyton rubrum*: exposure and infections within household groups. *Arch Dermatol* 1960;82:226-229
4. Baer RL, Rosenthal SA, Furnari D. Survival of dermatophytes applied on the feet. *J Invest Dermatol* 1955;24:619-622
5. Anstey A, Lucke TW, Philpot C. Tinea capitis caused by *Trichophyton rubrum*. *Br J Dermatol* 1996;135:113-115
6. Jones HE, Reinhardt JH, Rinaldi MG. A clinical, mycological and immunological survey of dermatophytosis. *Arch Dermatol* 1973;108:61-65
7. Zaias N, Rebell G. Chronic dermatophytosis syndrome due to *Trichophyton rubrum*. *Int J Dermatol* 1996;35:614-617
8. Mielsnen PG. Hereditary palmoplantar keratoderma and dermatophytosis. *Int J Dermatol* 1988;27:223-231
9. Novick NL, Tapia L, Bottone EJ. Invasive *Trichophyton rubrum* infection in an immunocompromised host. *Am J Med* 1987;82:321-325
10. Smith ER, Head ES. Subcutaneous abscess due to *Trichophyton mentagrophytes*. *Int J Dermatol* 1982;21:338-339
11. Wilson JW. *Trichophyton granuloma* (tinea profunda) due to *Trichophyton rubrum*. *AMA Arch Derm Syphilol* 1952;65:375-376
12. Chellan G, Shivaprakash S, Karimassery Ramaiyar S, Varma AK, Varma N, Thekkeparambil Sukumaran M, et al. Spectrum and prevalence of fungi infecting deep tissues of lower-limb wounds in patients with type 2 diabetes. *J Clin Microbiol* 2010;48:2097-2102
13. Bansal E, Garg A, Bhatia S, Attri AK, Chander J. Spectrum of microbial flora in diabetic foot ulcers. *Indian J Pathol Microbiol.* 2008;51:204-208
14. Choe SW, Yoon YH, Seo SH, Hong CK, Ro BI. A Case of Majocchi's Granuloma Caused by *Trichophyton rubrum*. *Kor J Med Mycol* 2004;9:49-53
15. Mayser P, Hensel J, Thoma W, Podobinska M, Geiger M, Ulbricht H, et al. Prevalence of fungal foot infections in patients with diabetes mellitus type 1 - underestimation of moccasin-type tinea. *Exp Clin Endocrinol Diabetes* 2004;112:264-268
16. Eckhard M, Lengler A, Liersch J, Bretzel RG, Mayser P. Fungal foot infections in patients with diabetes mellitus--results of two independent investigations. *Mycoses* 2007;50 Suppl 2:14-19